

Suspected Flunixin Poisoning of a Wild Eurasian Griffon Vulture from Spain

IRENE ZORRILLA,* ROSA MARTINEZ,* MARK A. TAGGART,† § AND NGAIO RICHARDS‡

*Environmental and Water Agency of Andalusia, Division of Integrated Environmental Quality, Center for Analysis and Diagnosis of Wildlife - CAD, Avda. Lope de Vega, 9, Málaga 29010, Spain

†Environmental Research Institute, University of the Highlands and Islands, Castle St, Thurso, Scotland, KW14 7JD, United Kingdom

‡Working Dogs for Conservation, 52 Eustis Road, Three Forks, MT 59752, U.S.A.

Abstract: *Exposure to residues of the nonsteroidal anti-inflammatory drug (NSAID) diclofenac present in livestock carcasses has caused extensive declines in 3 Gyps vulture species across Asia. The carcass of a wild Eurasian Griffon Vulture (Gyps fulvus) was found in 2012 on an Andalusian (Spain) game hunting reserve and examined forensically. The bird had severe visceral gout, a finding consistent with Gyps vultures from Asia that have been poisoned by diclofenac. Liver and kidney samples from this Eurasian Griffon Vulture contained elevated flunixin (an NSAID) levels (median = 2.70 and 6.50 mg/kg, respectively). This is the first reported case of a wild vulture being exposed to and apparently killed by an NSAID outside Asia. It is also the first reported instance of mortality in the wild resulting from environmental exposure to an NSAID other than diclofenac.*

Keywords: avian scavenger, diclofenac, ecopharmacovigilance, ketoprofen, nephrotoxicity, nonsteroidal anti-inflammatory drug, Old World vulture

Caso de Sospecha de Envenenamiento por Flunixin de un Buitre Leonado en España

Resumen: *La exposición a residuos de diclofenaco, un medicamento antiinflamatorio no esteroideo (AINE) presente en los cadáveres de ganado, causó graves pérdidas en las poblaciones de 3 especies de buitre en Asia. En el año 2012 se encontró un cadáver de un buitre leonado (Gyps fulvus) en una reserva de caza en Andalucía. Durante la necropsia se observó gota visceral severa, similar a las encontradas en los buitres de Asia envenenados por diclofenaco. A partir de muestras de hígado y riñón de este buitre se detectaron elevadas concentraciones de flunixin (un AINE) (valores medios = 2,70 y 6,50 mg/kg, respectivamente). Este caso es el primero reportado de un buitre expuesto y muerto por la exposición a un AINE fuera de Asia. También es el primer caso reportado de muerte en el medio natural debido a la exposición ambiental a un AINE distinto del diclofenaco.*

Palabras Clave: aves carroñeras, buitres del Viejo Mundo, diclofenaco, ketoprofeno, medicamentos antiinflamatorios no esteroideos, nefrotoxicidad, vigilancia farmacológica

§Address correspondence to M. Taggart, email mark.taggart@ubi.ac.uk.

Paper submitted August 25, 2014; revised manuscript accepted September 16, 2014.

Introduction

The role the nonsteroidal anti-inflammatory drug (NSAID) diclofenac has played in driving at least 3 species of Old World *Gyps* vultures nearly to extinction on the Indian subcontinent is well documented (Oaks et al. 2004; Pain et al. 2008). *Gyps* populations collapsed between 1992 and 2007 in India, falling by as much as 99.9%. Oriental White-Backed Vulture (OWBV) (*Gyps bengalensis*) populations declined by 43.9% per year between 2000 and 2007 (Prakash et al. 2007). The OWBV, once considered the most abundant bird of prey in the world (Houston 1985), was listed as critically endangered in 2000 (IUCN 2014). These declines have been driven by the widespread use of the veterinary NSAID diclofenac, which was (until recently) present in approximately 1:10 livestock carcasses available to vultures (Taggart et al. 2009). After diclofenac was established as the primary driver of the decline of *Gyps* vultures and a vulture-safe NSAID (meloxicam) was identified (Swan et al. 2006), diclofenac was banned for veterinary use across much of Asia (India, Pakistan, Nepal) in 2006 (i.e., Kumar 2006) to protect vultures.

Despite its known toxicity to *Gyps* vultures, in 2013, the Agencia Española de Medicamentos y Productos Sanitarios approved a request from a drug manufacturer to register diclofenac for use in pigs and cattle in Spain (VCF 2014). This licensing was condemned by many scientists and conservationists (e.g., Camiña et al. 2014; Margalida et al. 2014; VCF 2014), not least because Spain holds >95% of Europe's vultures.

Scavengers are exposed to NSAIDs, and other pharmaceuticals, when feeding on carcasses of treated livestock (Hayes 1988; O'Rourke 2002; Taggart et al. 2009). In parts of Europe, such carcasses are available at carcass dumps, at feeding stations, at captive facilities, and in remote areas where deceased animals (fallen livestock) are not retrieved. In Spain *muladares* (traditional carcass dumps maintained specifically for wild scavengers) are present across the country. The potential risk posed to scavengers by veterinary NSAIDs used in Europe, some of which have been identified as being of concern for avian scavengers (Cuthbert et al. 2007), has not yet been assessed. Although many NSAIDs have been approved for veterinary use for many years, to date little research has been undertaken to assess European scavenger exposure or to quantify residues of NSAIDs (or other pharmaceuticals) present in carcasses. In part, this may be because intentional poisoning of wildlife with pesticides and poisons (e.g., carbamates, strychnine) is currently considered a greater and more pressing threat (e.g., Sánchez-Barbudo et al. 2012).

We report on the results of an examination of a Eurasian griffon vulture (*Gyps fulvus*) carcass from Spain.

Its death was apparently due to renal failure and severe visceral gout, evidence of which was associated with elevated tissue levels of an NSAID (flunixin). We considered the implications of this for vultures and other avian scavengers in Europe relative to the recent licensing of veterinary diclofenac in particular, and to the many other NSAIDs already in use.

Methods

A Eurasian griffon vulture carcass was recovered on 18 July 2012 from a game hunting reserve in Andalucía during routine forensic investigations conducted as part of the Andalusian government's anti-poisoning and poaching strategy. It was submitted to the Center for Analysis and Diagnosis of Wildlife (CAD) in Malaga (Spain) for necropsy and toxicological tests.

In Spain deliberate wildlife poisoning is well documented (Sánchez-Barbudo et al. 2012). When acute toxicants (e.g., carbamates [CMs], organophosphates [OPs], strychnine) are ingested, death can occur almost instantly, while the poisoned food is still in the mouth or crop. Hence, tongue and mucosa from the crop and ventricle were excised for pesticide analysis. Pesticide residue extraction and screening (after Zoun & Spierenburg 1989) were conducted on the Eurasian Griffon vulture at CAD. Briefly, 5 g of sample was ground in a mortar with anhydrous sodium sulfate, extracted with dichloromethane, and cleaned up with solid phase extraction (SPE) cartridges. Extract aliquots were used for thin-layer chromatographic (TLC) pesticide screening. For OPs and CMs, validated limits of detection (LODs) for TLC, depending on the toxicant, were from 2 to 5 mg/kg.

Because the carcass presented with severe visceral gout (see Results), kidney and liver samples were also submitted to the Laboratorio Analítico Bioclínico (LAB) in Almería (Spain) for NSAID screening. This screening was conducted using 2 ultra-high pressure liquid chromatography (UHPLC) mass spectrometry (MS) systems (Waters Acquity UHPLC with tandem quadrupole MS; Transcend 600 UHPLC with single-stage orbitrap MS). Briefly, 5 g of liver and kidney were extracted into acetonitrile and methanol, centrifuged, filtered, then screened for diclofenac, 5 metabolites (4'-hydroxy, 5'-hydroxy, 3'-hydroxy, 4'5-dihydroxy, 3'-hydroxy-4'-methoxy diclofenac), and 7 other NSAIDs (flunixin, ketoprofen, meloxicam, carprofen, indomethacin, nimesulide, naproxen) following Gómez-Pérez et al. (2012) (LODs were 2–10 µg/kg).

Quantitative analysis for 9 NSAIDs with LC-MS/MS (Waters 2695 LC with MicroMass QuattroMicro MS/MS) was also performed on liver and kidney samples at the

Environmental Research Institute (ERI; after Taggart et al. 2009). Briefly, 0.5 g of tissue was extracted into acetonitrile with a homogenizer, and extracts were centrifuged, filtered, and analyzed using multiple reaction monitoring (MRM) transitions (limits of quantification were 5–20 $\mu\text{g}/\text{kg}$).

Results

This adult female Eurasian Griffon vulture was found on its back in good body condition with well-developed undamaged plumage (photos in Supporting Information). Based on rigor mortis stage, the bird was estimated to have died approximately 5–6 h before examination. Moderate autolysis was present, but no scavenging insects were observed on the carcass. The oral mucosa was unremarkable, and no identifiable food was seen in the mouth. Abnormal white precipitates, consistent with urate deposits, were clearly present on the surface of the liver and pericardium (Fig. 1a) and on the capsule and cut surface of the kidney (Fig. 1b). The crop was empty as were the proventriculus and ventriculus.

Pesticide tests for OPs and CMs were negative. Liver and kidney samples tested at LAB were negative for diclofenac and its metabolites. However, these samples were positive for flunixin at both LAB and ERI (Supporting Information). Quantitative analysis (ERI) showed the median flunixin level was 2.7 and 6.5 mg/kg in liver and kidney, respectively. The NSAID ketoprofen was also detected in the liver by LAB during screening; it was not found in the kidney. This NSAID was not detected quantitatively in either tissue at ERI; therefore, we considered this inconclusive finding incidental to the cause of death.

Discussion

This vulture was found <10 km from a muladar. Although it is impossible to link ingestion of flunixin to a specific carcass at this muladar, it seems plausible that this vulture was exposed when scavenging on a dead agricultural animal encountered in the field that was treated with flunixin shortly before death. This case is therefore important from a raptor conservation and policy standpoint because it is the first documented case of a wild vulture being exposed to and apparently killed by an NSAID outside Asia; it is the first clear case worldwide of a wild vulture apparently dying due to ingestion of an NSAID other than diclofenac; and the case, in light of the recent licensing of diclofenac in Spain (and in other parts of Europe), raises particular conservation concern. Specifically, it appears to demonstrate the real potential within Spain for this type of NSAID exposure scenario.

The levels of flunixin detected in the kidney and liver of this vulture are high. By comparison, investigations

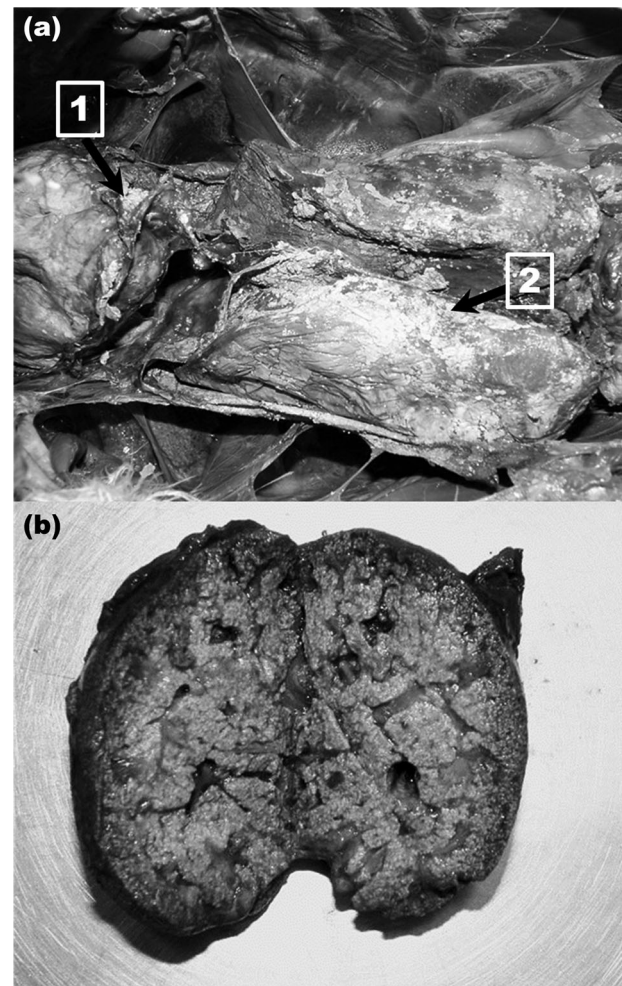


Figure 1. (a) Urate precipitates on the surface of the pericardial sac (arrow 1) and liver (arrow 2) of a Eurasian Griffon Vulture from Spain in which flunixin residues in liver were 2.7 mg/kg and (b) kidney of the same vulture showing urates throughout the renal tubules (white granules and stippling; flunixin concentration, 6.5 mg/kg).

regarding diclofenac poisoning in *Gyps* from Pakistan (Oaks et al. 2004) showed that wild OWBV found dead with renal failure and severe visceral gout had 0.051–0.643 mg/kg diclofenac in their kidneys. This study also reported maximum renal concentrations of diclofenac of 0.91 mg/kg in kidneys of OWBV that died after being experimentally dosed with 0.007–0.940 mg/kg (Oaks et al. 2004). Although the pharmacokinetics of flunixin in *Gyps* vultures is currently unknown, the levels detected in the Eurasian Griffon vulture in our study perhaps indicate exposure to a carcass of a very recently treated animal or ingestion of a meal containing a particularly high flunixin concentration.

More broadly, based on a recent survey of zoo and rehabilitation center data (Cuthbert et al. 2007), a wide range

Table 1. Nonsteroidal anti-inflammatory drugs (NSAIDs) allowed for veterinary use in Spain.*

<i>NSAID (approved for use in food animals?)</i>	<i>Type of animal</i>	<i>Maximum residue level ($\mu\text{g}/\text{kg}$) in edible parts</i>
Carprofen (yes)	bovine, equine	500—muscle 1000—fat, liver, kidney
Diclofenac (yes)	bovine	5—muscle, liver 1—fat 10—kidney
	porcine	5—muscle, liver 1—skin, fat 10—kidney
Firocoxib (yes)	equine	10—muscle, kidney 15—fat 60—liver
Flunixin (yes)	bovine	20—muscle 30—fat 300—liver 100—kidney
	porcine	50—muscle 10—skin, fat 200—liver 30—kidney
	equine	10—muscle 20—fat 100—liver 200—kidney
Ketoprofen (yes)	bovine, porcine, equine	not required
Meloxicam (yes)	bovine, caprine, porcine, rabbit, equine	20—muscle 65—liver, kidney
Metamizol (yes)	bovine, porcine, equine	100—muscle, fat, liver, kidney
Phenylbutazone (no)	equine	not determined
Suxibuzone (no)	equine	not determined
Tolfenamic acid (yes)	bovine, porcine	50—muscle 400—liver 100—kidney

*Derived from Commission Regulation (EU) No 37/2010 on pharmacologically active substances and their classification regarding maximum residue limits (MRLs) in foodstuffs of animal origin and Agencia Española de Medicamentos y Productos Sanitarios (www.aemps.gob.es).

of scavenging birds may be susceptible to an equally wide range of NSAIDs. In this survey, flunixin was shown to have caused mortality in 7 of 24 therapeutically treated birds of a variety of species (compared with mortality in 28 of 36 individuals from diclofenac and mortality of 0 of 739 individuals from meloxicam). The 7 birds that apparently died from flunixin therapy following a dose ranging from 1.0 to 4.5 mg/kg were a Ruppell's Vulture (*Gyps rueppellii*), a Crested Carriama (*Cariama cristata*), a Marabou Stork (*Leptoptilos crumeniferus*), an African Spoonbill (*Platalea alba*), and 3 Cinereous Vultures (*Aegypius monachus*). However, 16 birds (including Eurasian Griffon, Cinereous, and Ruppell's Vultures) did not die following flunixin doses of 0.5–12 mg/kg.

In other work, a Siberian Crane (*Grus leucogeranus*) was reported to have died after 8 d of twice daily injections of flunixin at 7.50 mg/kg (Langenberg

1995), whereas Klein et al. (1994) showed significant pathology in the kidneys of Northern Bobwhite (*Colinus virginianus*) following injection of flunixin at 0.100–32.0 mg/kg daily for 7 d. Several cases of presumptive flunixin nephrotoxicosis (in cranes and flamingos) have also been reported following administration for musculoskeletal problems (Klein et al. 1994). Finally, Ramzan et al. (2012) recently used flunixin (at 1.25 to 10.0 mg kg⁻¹) in chickens for 4 d. On the basis of mortality rates, visceral gout, and elevated uric acid levels in serum, the authors likened the toxicity of flunixin to that of diclofenac.

The case we report here may well be the tip of the iceberg. In Spain flunixin is registered for use in equine, bovine, and porcine medicine (Table 1). However, to our knowledge, no pertinent survey data estimating annual usage rates (by species, region, etc.) or any relevant carcass residue monitoring data are yet available (or

accessible) for Spain. Importantly, Spain hosts endangered Egyptian Vulture (*Neophron percnopterus*), near threatened Cinereous Vulture, and near threatened Bearded Vultures (*Gypaetus barbatus*) (IUCN 2014). With the exception of Egyptian Vultures, these species have been slowly recovering after decades of conservation effort across Europe (VCF 2014). Protected by European law, the millions of euros and human hours that have been invested to secure these species could now be jeopardized by the legal use of diclofenac, flunixin, and other NSAIDs (Table 1) (Cuthbert et al. 2007). New research (Sharma et al. 2014) also indicates that diclofenac may have caused eagle mortalities in Asia (Steppe Eagle [*Aquila nipalensis*]); hence, there are now concerns for species such as Bonelli's Eagle (*A. fasciata*), Golden Eagle (*A. chrysaetos*), and Spanish Imperial Eagle (*A. adalberti*), which all scavenge opportunistically on livestock carcasses in Spain.

The decision in Spain to approve diclofenac for veterinary use was made, and has not yet been reversed, despite the well-recognized toxicity of diclofenac to *Gyps*; that Spain is the primary territory of vultures in Europe (IUCN 2014); that certain Spanish and European vulture populations remain vulnerable; that muladares are present in Spain (and medicated carcasses do enter these); and that no robust (phase II) or relevant (to avian scavengers) risk assessment appears to have been undertaken or published (to our knowledge). One justification given for not reversing the licensing of diclofenac—despite there being many other alternative NSAIDs (Table 1), including at least one (meloxicam) that is widely considered vulture safe—is the assumption that Spanish vultures will not be exposed to NSAIDs in animal carcasses (as they are in Asia). However, this Spanish flunixin case involving a wild European Griffon Vulture provides indisputable evidence that medicated carcasses are being consumed by scavenging birds in Europe.

Given what has happened in Asia, it now seems imperative that a suitable level of eco-pharmacovigilance be established in Europe. We also argue that environmental monitoring of pharmaceutical residues in carcasses of animals that are available to scavenging raptors in Europe is now required. In Spain muladares receive animals that may have been given medication in the hours or days immediately prior to death—and it is exactly this scenario that has swiftly decimated vulture populations in Asia. Although NSAIDs are one group of compounds that should be targeted (Table 1), others such as barbiturates, antibiotics, and antiparasitics are also worthy of further investigation. Likewise, it seems prudent at this stage that centers dealing with wildlife mortality investigations (such as CAD) begin incorporating selected high risk compounds within their screening programs. This is particularly important when

postmortem findings (such as visceral gout) strongly implicate a specific compound class (such as NSAIDs).

We echo existing calls made by many researchers, conservationists, and conservation bodies (e.g., Camiña et al. 2014; Margalida et al. 2014; VCF 2014) to retract current licenses to use diclofenac as a veterinary medicine within Europe, especially in countries where livestock carcasses are commonly available to avian scavengers such as vultures and eagles. Given our findings, it also seems appropriate that the wider environmental risk posed by flunixin (and all other veterinary NSAIDs licensed in Europe [Table 1]) be re-assessed specifically with potentially vulnerable wide-ranging avian scavengers in mind.

Acknowledgments

We commend the dedication and work of the Spanish wildlife agents who recovered this vulture from the field. We thank G. Dowling, J. Tavares, V. Naidoo, A. Botha, and A. Camiña for additional information. The invaluable support of I. Fajardo (Dirección General Gestión Medio Natural, Junta de Andalucía), R. Arenas (Head of the Vulture Program), and the Vulture Conservation Foundation (<http://www.4vultures.org>) is gratefully acknowledged. We thank all CAD staff for their involvement and the personnel at LAB in Almería for their prompt analysis of these samples.

Supporting Information

Additional color photographs of this case and further LC-MS data are available online (Appendix S1). The authors are solely responsible for the content and functionality of these materials. Queries (other than absence of the material) should be directed to the corresponding author.

Literature Cited

- Camiña, A., J. R. Garrido, J. Martín, C. H. Lopez-Hernández, and R. Alfaro. 2014. A new threat to European vultures. *Science* 344:150.
- Cuthbert, R., J. Parry-Jones, R. E. Green, and D. J. Pain. 2007. NSAIDs and scavenging birds: potential impacts beyond Asia's Critically Endangered vultures. *Biological Letters* 3:91–94.
- Gómez-Pérez, M. L., P. Plaza-Bolaños, R. Romero-González, J. L. Martínez-Vidal, and A. Garrido-Frenich. 2012. Comprehensive qualitative and quantitative determination of pesticides and veterinary drugs in honey using liquid chromatography-orbitrap high resolution mass spectrometry. *Journal of Chromatography A* 1248:130–138.
- Hayes, B. 1988. British Columbia – deaths caused by barbiturate poisoning in bald eagles and other wildlife. *Canadian Veterinary Journal* 29:173–174.
- Houston, D. C. 1985. Indian white-backed vulture *Gyps bengalensis*. Pages 465–466 in I. Newton and R. D. Chancellor, editors. *Con-*

- ervation studies on raptors. Technical publication 5. International Council for Bird Preservation, Cambridge.
- IUCN (International Union for Conservation of Nature). 2014. The IUCN red list of threatened species. Available from www.iucnredlist.org (accessed August 2014).
- Klein, P. N., K. Charmatz, and J. Langenberg. 1994. The effect of flunixin meglumine (Banamine) on the renal function in northern bobwhite (*Colinus virginianus*): an avian model. Proceedings of the American Association of Zoo Veterinarians **32**:128-131.
- Kumar, A. 2006. Diclofenac for veterinary use: F. No. 18-03/2006/DC, Letter to All State Drug Controllers from the Drug Controller General (India), May 11, 2006.
- Langenberg, J. 1995. *Mycoplasma pododermatitis* (bumblefoot) in a Siberian crane (*Grus leucogeranus*). Proceedings of the Joint Conference of the American Association of Zoo Veterinarians, 284-285.
- Margalida, A., J. A. Sanchez-Zapata, G. Blanco, F. Hiraldo, and J. A. Donazar. 2014. Diclofenac approval as a threat to Spanish vultures. Conservation Biology **28**:631-632.
- Oaks, J. L., et al. 2004. Diclofenac residues as the cause of vulture population decline in Pakistan. Nature **427**:630-633.
- O'Rourke, K. 2002. Euthanatized animals can poison wildlife: veterinarians receive fines. Journal of the American Veterinary Medical Association **220**:146-147.
- Pain, D. J., et al. 2008. The race to prevent the extinction of South Asian vultures. Bird Conservation International **18**:S30-S48.
- Prakash, V., R. E. Green, D. J. Pain, S. P. Ranade, S. Saravanan, N. Prakash, R. Venkitachalam, R. Cuthbert, A. R. Rahmani, and A. A. Cunningham. 2007. Recent changes in populations of resident *Gyps* vultures in India. Journal of the Bombay Natural History Society **104**:129-135.
- Ramzan, M., M. Ashraf, and K. T. Mahmood. 2012. Toxicity of flunixin meglumine in broiler chickens. Journal of Pharmaceutical Sciences and Research **4**:1748-1754.
- Sánchez-Barbudo, I. S., P. R. Camarero, and R. Mateo. 2012. Intentional and accidental poisoning of wild and domestic animals in Spain: differences between regions. Revista de Toxicologia **29**:20-28.
- Sharma, A. K., et al. 2014. Diclofenac is toxic to the Steppe Eagle *Aquila nipalensis*: widening the diversity of raptors threatened by NSAID misuse in South Asia. Bird Conservation International **24**:282-286.
- Swan, G. E., et al. 2006. Removing the threat of diclofenac to Critically Endangered Asian vultures. PLoS Biology **4**:395-402.
- Taggart, M. A., K. R. Senacha, R. E. Green, R. Cuthbert, Y. V. Jhala, A. A. Meharg, R. Mateo, and D. J. Pain. 2009. Analysis of nine NSAIDs in ungulate tissues available to Critically Endangered vultures in India. Environmental Science and Technology **43**:4561-4566.
- VCF (Vulture Conservation Foundation). 2014. Diclofenac technical dossier. Available from www.4vultures.org/our-work/campaigning-to-ban-diclofenac-in-europe (accessed August 2014).
- Zoun, P. E. F., and T. J. Spierenburg. 1989. Determination of cholinesterase-inhibiting pesticides and some of their metabolites in cases of animal poisoning using thin-layer chromatography. Journal of Chromatography **462**:448-453.